

Clinical Exam: Made Easy.

#1) Nose

#2) Tonsils

#3) Tongue

#4) Maxilla

#5) Mandible



→ To determine nasal obstruction, ask patient:

“How troublesome is breathing through your nose?”

[0 to 100]: 20= mild, 40 =moderate, 60= fairly bad, 80=severe

Clinical Exam: Made Easy.

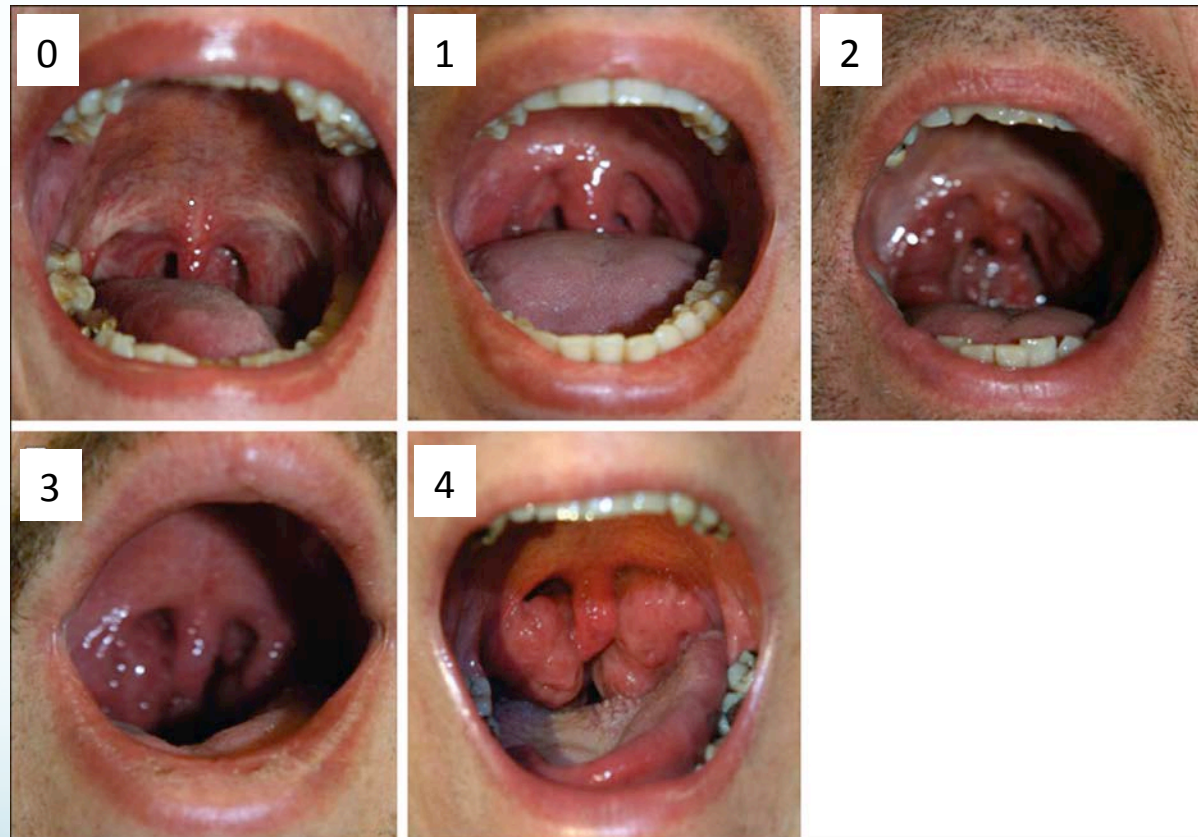
#1) Nose

#2) Tonsils

#3) Tongue

#4) Maxilla

#5) Mandible



Clinical Exam: Made Easy.

Mallampati *Tongue Position* Classification

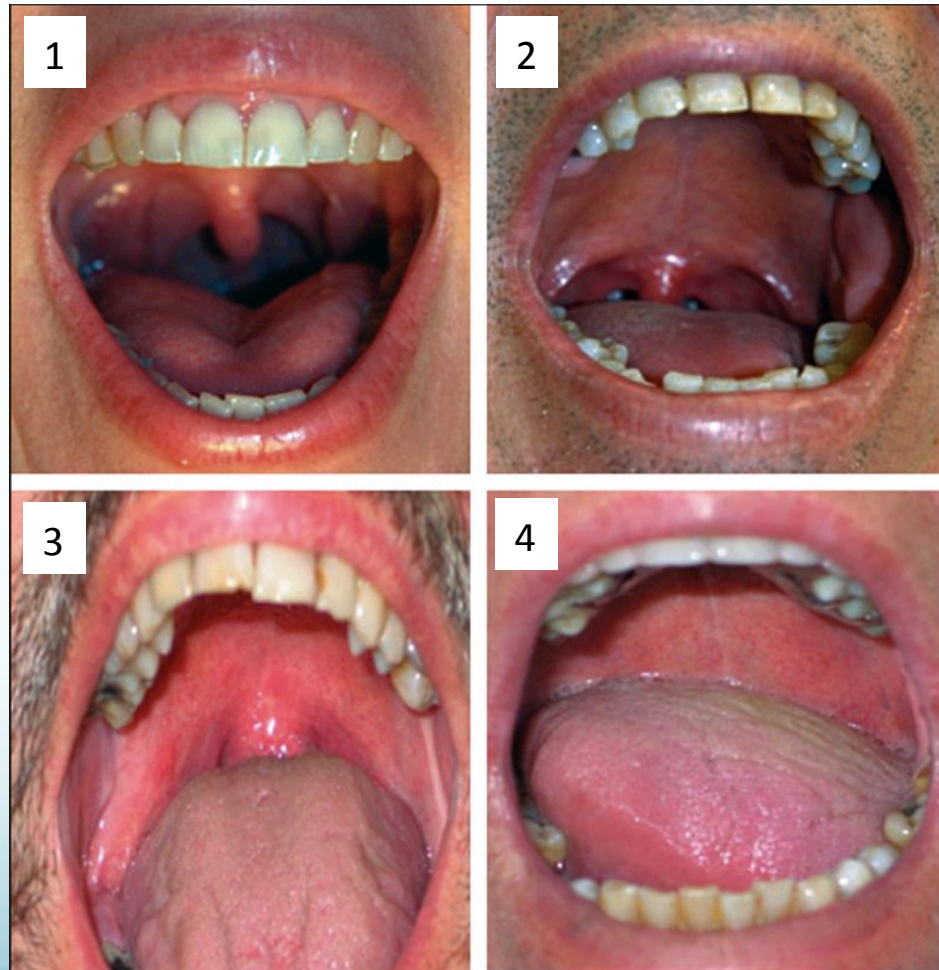
#1) Nose

#2) Tonsils

#3) Tongue

#4) Maxilla

#5) Mandible



Clinical Exam: Made Easy.

Functional *Tongue Range of Motion* Evaluation

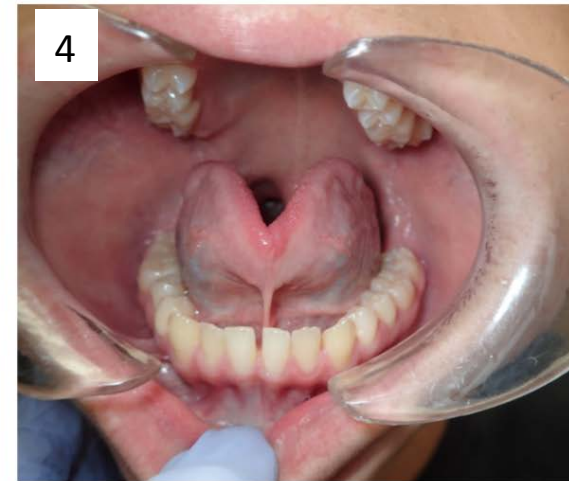
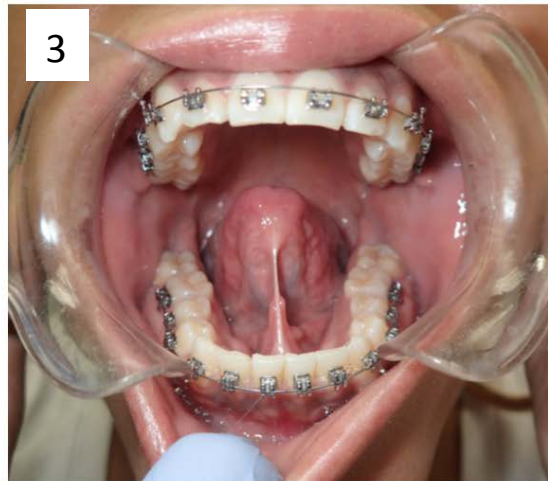
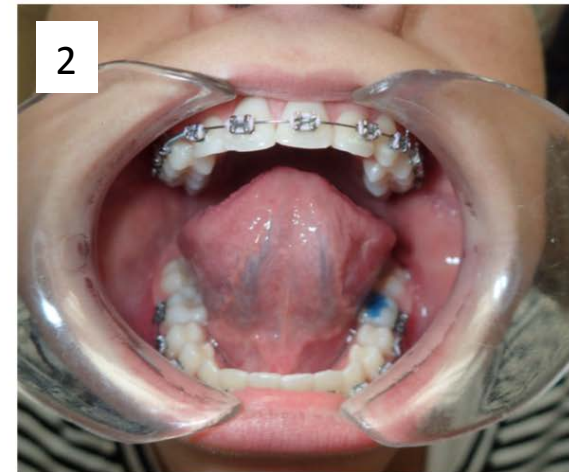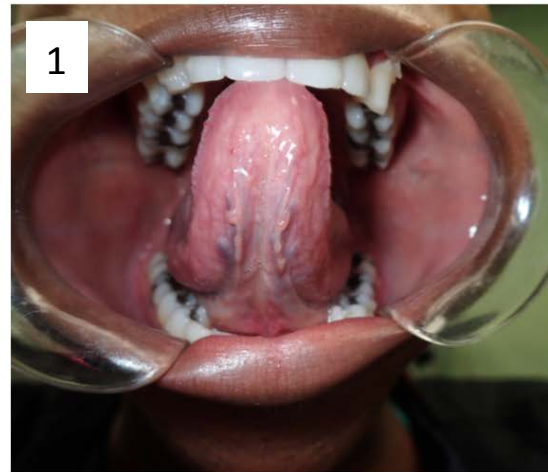#1) Nose

#2) Tonsils

#3) Tongue

#4) Maxilla

#5) Mandible



Clinical Exam: Made Easy.

Maxillary Deficiency

Transverse and/or Anterior-Posterior

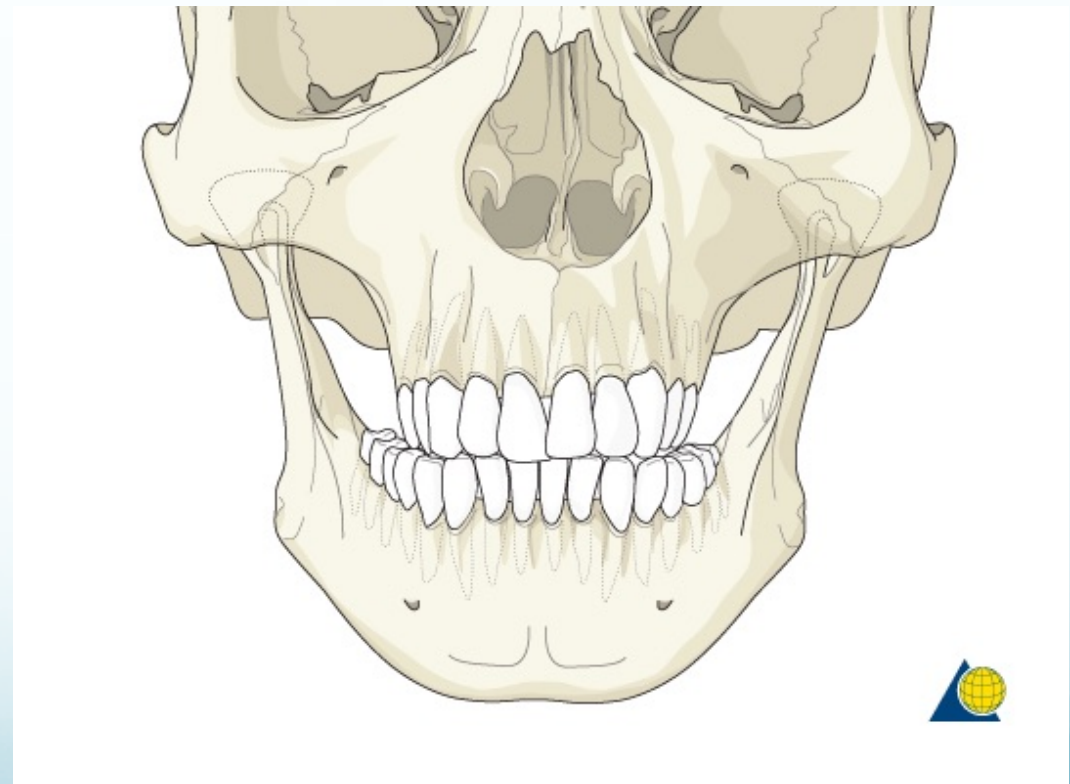
#1) Nose

#2) Tonsils

#3) Tongue

#4) Maxilla

#5) Mandible



Clinical Exam: Made Easy.

Maxillary Deficiency

Transverse and/or *Anterior-Posterior*

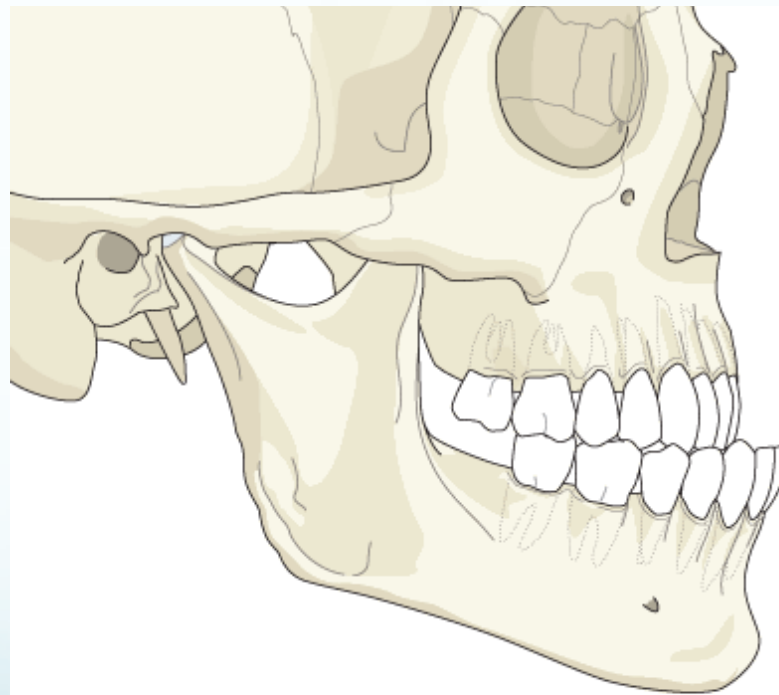
#1) Nose

#2) Tonsils

#3) Tongue

#4) Maxilla

#5) Mandible



Clinical Exam: Made Easy.

Mandibular Deficiency

Transverse and/or Anterior-Posterior

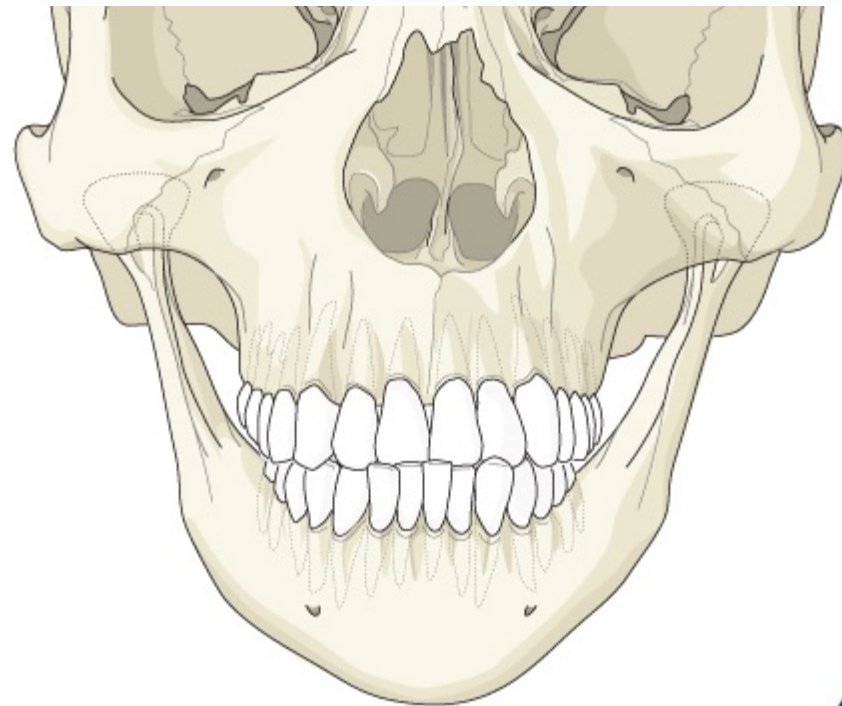
#1) Nose

#2) Tonsils

#3) Tongue

#4) Maxilla

#5) Mandible



Clinical Exam: Made Easy.

Mandibular Deficiency

Transverse and/or *Anterior-Posterior*

#1) Nose

#2) Tonsils

#3) Tongue

#4) Maxilla

#5) Mandible

